

# The Face of Neuro-Cutaneous Syndrome (NCS): New Cases, Recovery, and Perspectives

© By Omar M. Amin, B.Sc., M. Sc., Ph.D., USA

## Abstract

*Neuro-Cutaneous Syndrome (NCS) is a disorder primarily characterized by neurological crawling and pin-prick sensations and dermatological symptoms including itchy cutaneous sores. Many other neurological and dermatological imbalances are also involved. A cause-effect relationship has been established between toxic dental materials (cause) and NCS (effect). A protocol has been developed and NCS patients have been successfully treated at our Arizona-based Parasitology Center, Inc. (PCI). This article addresses the experience of 18 new patients seen at PCI and treated following our designated protocol. Of these, 6 patients have completed the protocol and have experienced full recovery.*

## Introduction

At Parasitology Center, Inc. (PCI), we have been researching NCS since 1996. Our early reports on this syndrome included the description of a case with many facial opportunistic infections from Oklahoma (Amin, 1996) and the first naming and diagnosis of the syndrome from 3 more cases, with a special reference to fibers and springtails (Collembola) (Amin, 2001). By 2003, we were able to provide a comprehensive diagnosis of NCS and establish the link to dental toxins as the causative agents. Amin (2003) clarified the nature of action of dental liners (bases) in the causation of NCS neurological and dermatological symptoms and provided the history of 3 NCS patients who have recovered following treatment thus establishing a cause-effect relationship. Various versions of this land-mark publication were subsequently published elsewhere (Amin, 2004 a, b, 2006a).

The above contributions were researched and published, and patients were successfully treated long before we discovered a similar clinical entity called Morgellons. The only difference is that we, at PCI, have done the research, established a causal relationship with dental toxins, developed a protocol, and successfully treated patients.

Most people have had dental work. Many have various degrees of sensitivity to some dental materials to which their bodies manifest varied intensities of symptoms. This epidemic-in-disguise has been routinely misdiagnosed by medical professionals who often label patients as delusional because of their unfortunate description of their neurological symptoms (actually caused by nerve damage) as having been caused by parasite infections. Amin (2004 c) specifically addressed this issue while discussing the clinical history of 24 NCS patients. Of these patients, 7 who have followed our protocol and completed treatment have experienced full recovery.

Amin (2005) provided an annotated list of about 400 dental materials that have been involved in the causation of NCS symptoms in patients that we have seen. Toxic ingredients common to all listed chemicals were classed in 4 categories. These categories are found in many more dental chemicals that were not reported in Amin's (2005) preliminary list. An overview of NCS (Amin,

2006 b) made special reference to organ system symptomology in 50 patients of both sexes and all age groups, misdiagnoses, storage organs, sealants, drug involvement, incubation period, and recovery, with the discussion of 5 relevant cases.

## Materials and Methods

Files of 18 new NCS patients of both sexes that have not been previously reported were selected. Availability of sufficient dental records and patients photos especially those showing their dermatological symptoms were required for each patient, with two exceptions. Patient's permission for use of their photos was obtained before hand. Sixteen females and two males are included. The information reported were substantiated with medical documents, dental histories, photographic records, personal observations and interviews involving data recorded in lengthy questionnaires. Patients were routinely followed up to monitor their progress. The follow up progress have occasionally been compromised when contact information change without forwarding notices.

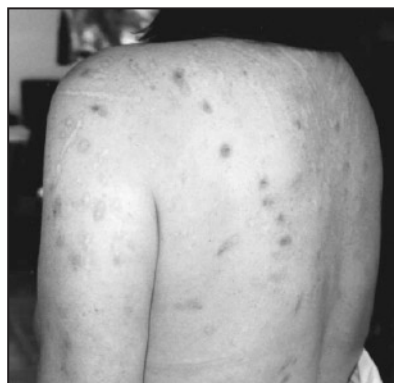## Results and Discussion

**1. JA** (Fig. 1. Lesions on the skin of JA were diffuse and usually more intense especially on the buttocks, thighs, and legs.) A white female born in Texas in 1958.

**SYMPTOMS:** JA was seen at PCI in December, 2006. She complained of "horrible itching, crawling pricks, sores, lesions from

scalp to feet for 4.5 years (since January of 2002). Some sores have hard white core with a dark spot." She was diagnosed as an NCS case with severe neurological and dermatological symptoms. Her skin sores were painful and oozing and equally diffuse throughout her body and elevated ripples, veins and tracts, and thrush around the lips were prominent.

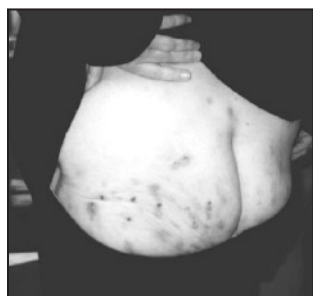Her neurological symptoms also included loss of memory, brain fog, and loss of concentration, body tremors, and compromised vision. She also experienced heart palpitations, high blood pressure, flu-like symptoms, intestinal abnormalities, bowel and breathing disturbances, tight chest, coughing, joint and muscular pain, and dental decay. She was also found to be allergic to metals, sulfa, noise, bright light, mold, and humidity. Her immune system was compromised and she experienced fatigue, nausea, insomnia, weight gain, and night fever and sweats. JA was previously diagnosed as delusional by other practitioners. She has used up to 66 different medications, lotions, ointments, creams, sprays, soaps, antibiotics, and supplements but at no avail.



**DENTAL HISTORY:** JA's major dental work in 1981-82 involved the use of Esthet x, Esthet x flow, Prime & Bond, ED Primer-liquid A & B, A & B-Paste, Caulk, and Concrete. The latter two dental materials included no identifiable hazardous ingredients but all the others included various methacrylate and dimethacrylate resin. The first two also included Titanium dioxide.

**CONCLUSIONS:** JA's blood biocompatibility test results are not available to date. However methacrylate and dimethacrylate compounds and titanium are known dental toxins causing NCS symptoms in reactive patients especially those allergic to metals (Amin, 2005). The compromised neurological and organ systems functions were shown to be caused by methacrylate compounds (Amin, 2006 b). In recovering patients, all imbalances were shown to be reversible, including those involving nerve tissue. The special importance of toxic organ systems as storage organs of dental toxins serving as secondary foci of symptoms even after total dental rehabilitation was discussed by Amin (2006 b).

**NOTE:** JA started our treatment protocol but we do not know if she started her dental rehabilitation because we have lost contact with her since.



**2. TB** (*Fig. 2. Lesions on the skin of TB were especially pronounced on the buttocks.*) A white female born in Texas in 1951.

**SYMPTOMS:** Patient was seen at PCI on January 11, 2007 complaining of slow healing diffuse skin lesions on various parts of her body and hair loss and fibers, as well as neurological

symptoms including pin-prick, crawling, and burning sensations, and brain fog, loss of vision, difficulty processing thoughts, and poor concentration since 1995. Upon examination, she was also shown to experience open and itchy lesions, elevated ripples and tracks, with history of springtails in 2004 and unidentified fungus infection in 2000. She also experienced organ system imbalances including high-blood pressure (1995), intestinal abnormalities (2000), bowel disturbances (1997) kidney problems (1997-2000), joint and muscular pain with mild arthritic symptoms (1997). Her oral abnormalities included dental decay and abscesses, and painful roots (1995). She was mildly sensitive to bright light and noise. She was fatigued with compromised immune system who often experienced insomnia and psychological trauma. She was treated for severe depression since 1995 with daily doses of 100 µg of Zoloft and 10 µg of HBP, and for elevated cholesterol. She was regularly treated with cortisone especially after her complicated hysterectomy in 1995. Three dermatologists (1996-2000) declared her normal but gave her antifungal compounds and more cortisone that caused the worsening of her skin condition. A swab from her abdomen and arm taken on January 17, 2007 was negative for infections. She self medicated using a wide variety of creams and lotions but at no avail. More recently, her skin sores became very dry and unbearably itchy especially around trunk area with a pervasive sulfur smell. TB has been following our protocol since January, 2007.

**DENTAL HISTORY:** A total of eight teeth were compromised with Dycal and Fynal since 1992. All teeth had negative charges ranging from -10 to -42. Other dental materials used included Rely x, Clearfil, Gluma and Optibond, IRM, Gutta Percha, and Eugenol. All these compounds were demonstrated to be toxic to sensitive patients experiencing NCS symptoms

(Amin, 2003, 2005). Unidentified acrylic (for temporary crowns) and porcelain were also used. Following biocompatibility test results, TB had 6 of the eight compromised repaired in February and March, 2007. The two other teeth were decomposing, # 5 with a root canal and # 31 with a nickel composite. They were extracted in April, 2007.

**CONCLUSIONS:** TB's biocompatibility test results show that she is highly reactive to Optibond and Gluma, both are methacrylate- and hydroxyethyl- methacrylate- based compounds, and to nickel. The composite used in the recently extracted decomposed tooth # 31 was nickel-based. We do not know what kind of porcelain alloy was used and, thus cannot establish its possible involvement in TB's toxicity picture, if any. An incubation period of about three years can be established between the major dental work in 1992 and the first appearance of symptoms in 1995.

**RECOVERY:** TB started showing signs of recovery since February 2007, in a relatively short period. This parallels the fact that her organ systems were not seriously impaired by her dental toxins thus faster healing despite her rather severe dermatological and neurological symptoms. On April 3, 2007 TB wrote "I am happy to report that I am at last finished with all the dental work required. It appears that less and less debris is coming from my skin during the ... applications ... my skin situation has improved ... I am continuing with all other aspects of the protocol." On August 16, 2007, TB wrote "I had to interrupt the detox program on 2 different occasions. My skin has improved significantly this summer, in spite of the interruptions. I am completely optimistic and will continue to work on it until it is completely back to normal."

**3. DB** (Photos unavailable) A white female born in B.C., Canada in 1954

**SYMPTOMS:** When DB was first seen at PCI in January of 2006 she was complaining from "chronic fatigue, brain fog, low white blood cell count, abdominal chest and joint pain, hair loss, pussy scalp sores that do not heal, tingling of mouth and extremities, and inability to tolerate the sun when experiencing a flare up of symptoms" which she experienced every 3-4 weeks along with high temperature, vision problems, and body odor. About fifteen years ago, she experienced many facial sores after major dental work and after the use of sulfa drugs. The intensity of her symptoms varied from time to time since. Additional neurological symptoms became evident upon examination. These included severe pin-prick and movement sensations, loss of memory, poor concentration, and vision problems. She also experienced moderate to severe endocarditis, heart palpitations, high blood pressure, flu-like symptoms, intestinal abnormalities breathing disturbances, coughing, tight chest, muscular pain, arthritic symptoms, inflamed gum tissue, dental decay, and painful roots. She was especially sensitive to light, noise, electro-magnetic fields, and mold. She was severely immune compromised and experienced night fevers and sweats.

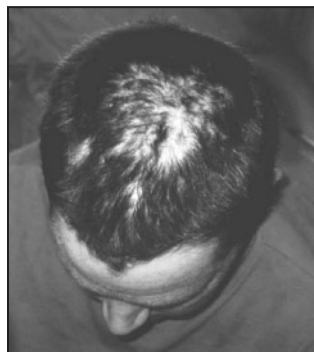In April of 2005, histo-pathological sections from a wedge-excision biopsy of sub-damaged skin from the right lower eyelid showed moderate hyperkeratosis of the epidermis with follicular plugging and chronic inflammatory infiltrate mostly of lymphocytes suggesting hydropic degeneration. A few necrotic keratinocytes and thickened basement membranes were also noted. The pathology report attributed these findings to possible lupus erythematosus while, from our experience at PCI, they are consistent with findings from NCS patients (Amin, 2003, 2004 b). Her blood tests did not indicate the involvement of lupus.

**DENTAL HISTORY:** DB had extensive dental history with many root canals, cavities, crowns, veneers, and bridges with many infections since she was six years old but her dental records go back only to 1994. She had two severe bouts of TMJ in 1986 after having six crowns done. Ten years later, she had eight crowns done in a short time followed by worse TMJ symptoms. Wearing a splint then did not help. Adjustments resolved some of the symptoms but a more recent filling of three teeth caused serious illness. During this episode, all her gums were inflamed and bleed profusely with mild brushing. Like her father and brother, she showed severe allergy to sulfa drugs.

Dental materials used since 1994 included Dura Seal, Ketac, Etch (1994), Ketac, Dyract (1996), Ketac (1997), Prime & bond, Gutta percha, Dycal, Diamond link, Temp bond (1999), Zone, Ticore, Dura flora (2000), Fuji, and Sealapex (2001). All these dental material were shown to be toxic to sensitive NCS patients (Amin, 2005) depending on their level of reactivity. DB's blood biocompatibility test results show high reactivity to at least to Sealapex, Ketac, and Dyract. We do not know what dental products were used between 1960 and 1994.

**CONCLUSIONS:** DB's symptoms, dental history, bio-compatibility test results and histopathological pathology clearly incriminate NCS as the cause of her clinical disorder; see Amin (2003, 2005, 2006 a). The involvement of her organ system was demonstrated as a result of toxicity associated with dental materials (Amin, 2006 b). It is not possible to determine the incubation period in this case since her dental history before 1994 is not known.

**NOTES:** DB has used the initial four-month supply of remedies since we have seen her in January of 2006 but has not reordered any since. She has not gone through proposed dental rehabilitation and is currently pursuing treatment of a 2005 presumptive diagnosis of lupus. We regret DB's lapse of follow up on her NCS treatment but hope to hear back from her again soon.



**4. DC** (Fig. 4. A scalp sore on the head of DC. Large dark sores were observed elsewhere on her skin especially the legs.) A white female born in Wisconsin in 1955.

**SYMPTOMS:** DC came to PCI in September, 2006 complaining of "fatigue, abnormal hair growth, fibers, skin sores, poor concentration and joint and muscle soreness." Upon examination, DC was documented to

have severe degrees of all dermatological and neurological symptoms and moderate intensities of organ system and oral cavity symptoms characteristic of classical NCS cases for the 3-6 month period preceding her visit to PCI. Her dermatological symptoms included itchy, open oozing, painful sores and lesions on the skin and scalp, elevated ripples, tracks and bumps, and presence of fibers, fungus and springtails (Collembola). Her neurological symptoms included skin irritation, pin-prick, crawling and movement sensations, poor memory, concentration and vision, brain fog and body tremors. Organ system symptoms included heart palpitations, flu-like symptoms, compromised intestinal, kidney, respiratory, muscular, joint and liver functions. Her oral cavity symptoms included inflamed gum tissue, gray and decaying teeth, mucoid secretions, painful roots, and thrush around lips. She also demonstrated severe allergies to light,

noise, electro-magnetic fields, mold, and humidity. Additional general symptoms included insomnia, compromised immune system, night fever and sweats, psychological trauma, and weight loss. She also had one presumptive diagnosis of Lyme Disease in June, 2006. Treatment with unspecified antibiotics and herbs for three weeks and four months, respectively, provided some brief but temporary relief.

**DENTAL HISTORY:** DC's available dental history goes back to 1995 during which Gutta percha was used in two teeth, Fuji 1 was used in another tooth and Vitra bond in a fourth tooth. The first is a zinc oxide product and the latter two are methacrylate-based. All above products are known to cause NCS in sensitive patients (Amin, 2005). We do not know DC's dental history before 1995.

**CONCLUSIONS:** DC's dental history, symptoms, and clinical history are consistent with demonstrable NCS cases. No blood bio-compatibility test or dental rehabilitation were undertaken as of the date of this writing. However, methacrylate-based compounds and zinc oxide are known causative agents of NCS (Amin, 2005, 2006 a).

**NOTES:** DC has continued to use our recommended supplements and detoxifying remedies through May, 2007 and has felt better. However, following up on the rest of our protocol recommendations is a must if she is to achieve complete recovery.

**5. OD** (Photos Unavailable). A white female born in New York in 1958.

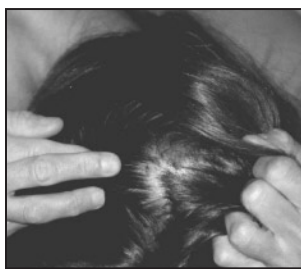**SYMPTOMS:** OD presented at PCI in April, 2006 with classical neurological NCS symptoms including moderate to severe skin irritation pin-prick, crawling and movement sensations. These sensations created the illusion of mite or parasite infections. Other neurological symptoms related to memory, tremors, and vision were mild. Her skin was not compromised. She experienced mild heart palpitations and insomnia, and high blood pressure and psychological trauma. She noted allergy to sulfa.

**DENTAL HISTORY:** OD was thirteen years old when she had her first dental filling. History of Dycal use was noted. Many of her permanent teeth are missing; she has a partial. Top middle four teeth have been bonded and two posts planted in top right and top left sides. She has undergone dental rehabilitation after her bio-compatibility test results became available. The final phase of her dental rehab is being completed at the time of this writing.

**CONCLUSIONS:** OD's bio-compatibility test results show high reactivity to Dycal; the same liner placed in her teeth. Her allergy to sulfa, a major component of Dycal's ethyltoluene sulfonamide, supports the above association. Her organ system involvement in the storage and dissipation of dental toxins (Amin, 2006 b) is likely since her neurological symptoms continued after the loss of many of her original teeth and before she underwent her recent dental rehabilitation. Not enough information is available to determine her incubation period.

**RECOVERY:** In January, 2007 and before her final dental rehabilitation session, OD wrote that after having "the old dental materials removed and replaced with materials (indicated as) ... low reactive on my blood (biocompatibility) test ... almost immediately all of the neurological symptoms went away and my health totally restored. I take this as a serious gift." We would like to use this case as another demonstration of the cause and effect relationship validating our work on the dental toxin's (cause) relationship to NCS (effect) and the efficacy of our protocol in changing outcome.





**6. LF (Fig. 5.** *A scalp sore on the head of LF*). A white female born in Minnesota in 1954.

**SYMPTOMS:** LF's symptoms started in 2002. At PCI, LF presented with severe dermatological symptoms of sores, open lesions, tracks, bumps and peeling skin and fibers. Her sores and lesions

were particularly evident on the scalp where we took swabs for culturing. Culture revealed infection with *staphylococcus aureus* and *S. epidermidis*. She also complained of severe crawling and movement sensations and moderate memory loss, brain fog, and poor concentration, as well as flu-like symptoms, joint pain, and arthritic symptoms. She was sensitive to noise, mold and humidity and recently experienced fatigue, insomnia, compromised immune system, and night fever/sweats. She was also diagnosed and treated for strep throat on multiple occasions. She experienced no improvement. Despite her aggressive antibiotic regimen, including Keflex, PenVeek, Amoxicillin, Bactrim, and Minocycline hydrochloride. LF's scalp sores were erroneously diagnosed as being caused by a "possible scalp parasite" in November, 2006. Treatment with Lindane did not resolve the problem. The scalp lesions were ulcerated and measured about 1 cm in diameter. Overlying her scalp, erythema and crusting were observed in March, 2007. However, over the vertex scalp, there were alopecic plaques and induration. 4 mm punch biopsies of the plaques were performed then. Compact hyperkeratosis, acanthosis, upper dermal fibrosis as well as perivascular and perifollicular chronic inflammation were noted. These findings were interpreted as "suggested of traction alopecia . . ."

**DENTAL HISTORY:** Three molars were filled in 1981. The nature of these fillings have not been ascertained and no further dental work was done for LF since.

**CONCLUSIONS:** LF's symptoms, lesion pathology (Amin, 2003 ) and experience are typical of NCS cases. However, she is atypical in that the onset of her symptoms in 2002 appears to be related to non-dental causes. In 2001, LF was diagnosed with complex comminuted fracture of the left calcaneus. This fracture was repaired in June, 2001 using a stainless steel/nickel calcaneal plate. In August, 2004, she was diagnosed with peroneal tendinitis in the same location. In January, 2007, she was evaluated for metal allergy. We, at PCI, recommended a biocompatibility test. The test results dated 5/4/07 demonstrated moderate reactivity to nickel which we believe to have been the primary cause of her NCS symptoms. We recommended the removal of the plate. We have previously seen rare cases of NCS resulting from allergies to chemicals not related to dental materials, e.g., recreational drugs (Amin, 2006 b), cleaning agents, or fumes from occupational exposures.

**NOTES:** No follow up information is available. In our last contact with LF, however, she indicated that she will have the plate removed.

**7. SG (Photos unavailable).** White female born in 1955 in Ohio.

**SYMPTOMS:** We first saw SG in April, 2006. She was complaining from "severe itching-black debris comes out of skin, crawling sensations in face and legs-lesions getting worse. Fibers emerging from skin ... pin-prick sensations." On checking her clinical history it was found out that her symptoms began in July, 2005 with severe scalp itching followed by pin-prick sensation and lesions in the back that later spread all over the body and coupled with burning sensations. The face was particularly affected.

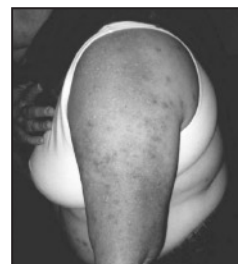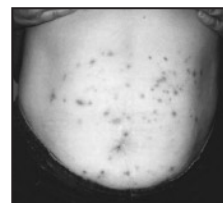
Crawling sensations began on upper thighs and the itchy burning oozing lesions spread further with the crawling feelings becoming more intense especially in the scalp in the early morning and evening. Body and hair seemed to be full of static electricity (as measured by a voltmeter) with considerable skin flaking and occasional night sweats. Additional symptoms included body tremors, vision problem, compromised memory, and poor concentration. Breathing disturbances, coughing and tight chest were also noted. SG also reported allergies to sulfa, penicillin, and electromagnetic fields. SG has independently taken the following medications: Flagyl, Stomectol, Biltricide, Thiabendazole, Medendazole, Albendazole, Itraconazole, Fluconazole, Levaquin, Bactrim DS and many vitamins and supplements. A swab from her chest was negative for bacteriological or fungal infections.

**DENTAL HISTORY:** SG's dental history was largely wanting except for the noted use of Revolution-Formula 2, a "flowable light cure composite" made of methacrylate ester monomers reported to be toxic in sensitive NCS patients (Amin, 2005). Dates and extent of use were not known.

**CONCLUSIONS:** SG is clearly an NCS case that was previously diagnosed with "dermatitis." Her dermatological, neurological, and systemic symptoms are clearly consistent with those described in NCS patients (Amin, 2001, 2004b, 2006b). She has used our recommended supplements and detoxifying remedies initially but did not follow up on the rest of the protocol. She did not do her dental rehabilitation or the dental biocompatibility test, and her dental history remains incomplete.

**NOTES:** SG has experienced some improvement in her symptoms following the initial use of our recommended supplements and homeopathic detoxifying agents. However, the limited term use of these products and the neglect of dental rehabilitation and other proposed detoxification therapies did not allow her recovery. SG's lack of follow up and her attempts to resolve her issues through other supplements and through the management of genetically modified substances have not yielded detectable benefits. Her symptoms profile remains unchanged.

**8. PJ (Fig. 7.** *Crusty inflamed sores covering the arms of PJ.* **Fig. 8.** *Additional sores on the abdomen of PJ.* *Sores also covered her face and legs*). White female born in 1953 in California.

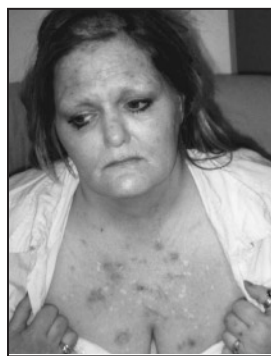

**SYMPTOMS:** In October, 2005, PJ was seen at PCI complaining of "skin irritation, non-healing, hard, that do not go away, open oozing fluid under skin, red sores, muscle pain, weakness, memory, eye, and language problems." Her husband was noted as "not affected or bothered by it." Her dermatological symptoms (itchy painful lesions and sores, elevated tracts, peeling skin, scalp sores) were severe but in cycles since 1975. Her neurological symptoms (skin irritation, pin-prick, burning and crawling sensations, brain fog, poor concentration, body tremors, memory and vision problems) were also severe but mostly since 1995; 20 years after the dermatological symptoms. Organ symptoms included some heart palpitation and intestinal and bowel disturbances. She also noted allergy to sulfa and experienced dental decay with painful roots and graying teeth. The decay usually involved sites under crowns. She was diagnosed as psychotic in 2004, with depression in 1995, and was regularly anemic.

She works in a machine shop and only Zolof provided temporary relief. A swab culture from the abdomen proved negative for bacteriological and fungal infections. Test for recreational drug use proved negative.

**DENTAL HISTORY:** PJ's dental work started when she was a young girl but her dental history was documented in thirteen teeth in only six years, 1999-2005, during which time Dycal, Optibond, and Zoe were used. We do not know her dental history before 1999. We do know, however, that she has not started her dental rehabilitation as of to date and that her dentist would not work with her. She also noted that our recommended vitamin supplements did not work for her (?). Her serum biocompatibility test showed that she is highly reactive to Zoe.

**CONCLUSIONS:** As of July, 2007, PJ still have not implemented any of our protocol recommendations except for having had the biocompatibility test. All documented dental materials used. e.g., Dycal (ethyltoluene sulfonamides, Zinc oxide, etc.), Optibond (uncured methacrylate monomers), and Zoe (Zinc oxide) are known dental toxins in allergic patients (Amin, 2005). She is clearly allergic to sulfa (as she noted) in the Dycal and to the Zinc oxide in Zoe. Her incubation period was 30 + years for dermatological symptoms but only about ten years for neurological symptoms. This indicates that, at least in this case, the neurological symptoms take considerably longer time to manifest than the dermatological symptoms.



**9. SK (Fig. 9. Sores covered the scalp, face and chest of SK as well as her arms and legs. Sites of old resolved sores are marked by loss of melanin).** White female born in 1962 in Spokane Washington.

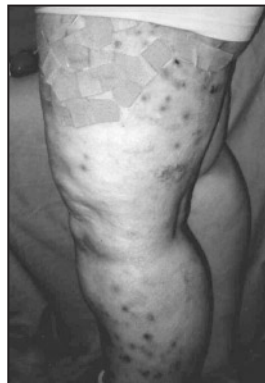**SYMPTOMS:** In October, 2006 SK presented with severe dermatological symptoms that started in May, 2003 and included diffuse open, painful, oozing, and itchy lesions and sores, as well as tracks, ripples, and peeling skin.

Especially noted was a large coalescing sore on her scalp which cultured positively for, *Staphylococcus aureus* causing considerable loss of hair. Her neurological symptoms started in October, 2005 and included pin-prick, crawling, burning sensations, brain fog, poor concentration, and compromised memory and vision. SK's severe organ system symptoms started in October, 2005 and included intestinal and bowel disturbances, vomiting, flu-like symptoms, compromised kidney function, swelling, joint and muscular pain. She also experienced inflamed gum tissue, dental decay, abscesses, and painful roots. She noted allergies to sulfa, aspirin, light, noise and mold. She was also fatigued, nauseated with psychological trauma and night fever and sweats. Practically all SK's symptoms were severe in intensity. As with PJ, SK's dermatological symptoms started earlier than her neurological and organ system symptoms. She was diagnosed with shingles and M.R.S.A., self-inflicted and meth addict sores, in late 2004, crazy and with impetigo in early, 2005. She seemed perfectly normal (not crazy), but severely compromised. She has received no previous medical treatments.

**DENTAL HISTORY:** SK lost 17 teeth in one year with severe swelling and complications. Her dental records beginning in 1991 included the use of Gutta percha (Zinc oxide), Temp bond (Zinc oxide), 3m ESPE (dimethacrylates, methacrylates), and Thermofill (a methacrylate composite), all of which are known dental toxins in sensitive NCS patients (Amin, 2005).

**CONCLUSIONS:** SK's dental history and pathology established her as a genuine NCS case. She, however, did not take our recommend remedies at the time of her visit to PCI in October, 2006 and apparently is not following up on her protocol. We do not know her present status and have no reason to believe that she has realized any improvements. Her incubation period is estimated to be at least 12 years, from 1991 to 2003. We do not know her dental history before 1991. SK's case is only included in this work because it adds more support for the already established relationship between dental causes and NCS pathological outcome.

**10. BL (Fig. 10. Sores on the legs of BL Her sores were diffuse and covered the face, chest, trunk, and arms).** A white female born in Meriden, Connecticut in 1950.

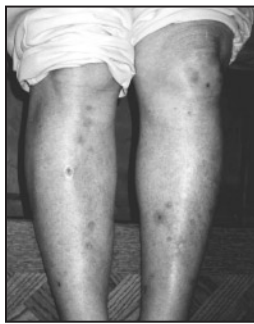

**SYMPTOMS:** When BL was first seen at PCI in February, 2006, she was complaining from high intensities of all dermatological, neurological, organ system and oral symptoms noted by above patients. As with the previous two patients, dermatological symptoms appeared first in 2002 followed by constant neurological symptoms between 2002 and 2004. Organ system, general and oral symptoms occurred between 2001 and 2002. All symptoms were of a constant nature that were experienced regularly. BL also experienced hair loss, anemia, teeth breakage, pain deep in the bone, ringing in ears, constant headaches especially around eyes and temples, light-headed, ADD-like symptoms, and Parkinson-like symptoms. She was previously diagnosed with "paranoid parasitosis, cutaneous larval migrans, and bacterial infections." Her "scars on her face and nose ... , two open wounds on the right cheek area measuring about 2 mm in diameter" in August 2004 were diagnosed as "patient has self-infecting mental disorder" by an infectious disease clinic. The same clinic assessed BL as "with a generalized cutaneous disease most likely from a cutaneous larval infection" without having isolated or identified any such larvae. In October, 2004, the same clinic persisted in diagnosing BL with "atypical cutaneous worm infection" and in June, 2005 with "neurodermatitis as well as parasitic infestation." See Amin (2004 c) for discussion of misdiagnoses by medical professionals. Patient had no history of illegal drug use but had used prescribed Hydrochodone, Fricicet, and Celebrex. A culture swab from BL's hand and arm proved negative for bacteriological and fungal infections.

**DENTAL HISTORY.** BL had many dental fillings since 1986, root canals and braces since 1991, and caps and metal posts since 2001. Old dental restorations were made out of silver alloy mixed with mercury and more recently using composites that are acrylic based. After her first auto-accident in 1995, a mouth piece made of heat-cured Polymethyl-methacrylate was used and a porcelain was constructed to semiprecious metal crown that was subsequently lost. A clinical examination in 1992 showed teeth nos. 1, 2, 15, 17, 18, 31, and 32 to have been lost and teeth # 3 (with composite), and nos. 8, 9 (chipped). TMJ and other corrective dental procedures were performed. Her second car accident in 1999 complicated her dental and immunological picture further. Four surgeries followed her first car accident but her immune system totally broke down after her second car accident which apparently heightened the intensity of her reactivity to her dental toxins. The jolt to her body and damage to her oral aperture may have conceivably caused the release of more of her dental toxins into the circulation.

**CONCLUSIONS:** Much of BL's dental record remains wanting. However, the use of the acrylic-based mouth piece, the state of her dental health, and the severe intensity of her symptoms render her a classical NCS case. One additional tooth was extracted in 2006 after the silver/mercury amalgam had fallen out and the tooth had spilt down the center. We have no evidence that her blood biocompatibility test was done but we do know that she has been taking the detox remedies and supplements at least through the summer of 2006. She has had all her remaining teeth rehabilitated (or extracted) as of July, 2007 when she declared that she will do her best to follow our protocol.

**NOTES:** Five months after we had our first meeting in February, 2005, BL has already observed some progress. In May, 2005, she wrote "I know the difference between before I saw you and now." In another note in the same month, she wrote "evidently, due to a car accident in 1999, my jaw was thrown off center and my teeth were hitting in a angle, thus causing my teeth to crack below the gum line. The toxic vapors leaked into my system, already suppressed due to chronic pain from the injuries caused by the accident. When I met Dr. Amin at the Parasitology Center, Inc ... I was actually near death. I was diagnosed with not only a classic case of Neuro-Cutaneous Syndrome, but a **severe** case." In a phone conversation in May, 2007, BL stated that she feels better, broken teeth are out, and her skin is better even though she was still taking some pain medication (accident related) but considerably less.



**11. JM** (Fig. 11. Sores on legs of JM. Her sores were also notable on her arms). White female born in Kentucky in 1961.

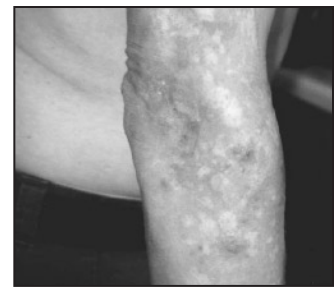
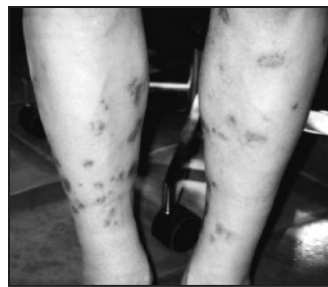**SYMPTOMS:** When we saw JM at PCI in September, 2005, she was complaining from "open lesions, filaments, swelling ankles and feet." Further examination showed that she was experiencing diffuse and severe open, itchy, oozing and painful lesions with tracks, bumps, peeling skin and scalp sores for three months to one year in 2004. A swab from leg sore proved positive for *Staphylococcus epidermidis* in 2004. Her neurological symptoms included severe pin-prick, crawling, burning and movement sensations, memory loss, brain fog, body tremors, and compromised vision for one year. Organ system symptoms included severe heart palpitations, high blood pressure, and moderate respiratory problems, tight chest, swelling, joint and muscular pain, and arthritic symptoms for ten years. Her gum tissue was inflamed for one month. She was also fatigued with moderate nausea for nine months and suffered severe psychological trauma and frequent night fever and sweats. She was previously diagnosed with "poor circulation; the reason for her lesions not healing."

**DENTAL HISTORY:** JM's dental history was made available from a single dentist since 1975. Aside from the many poorly documented repairs, fillings, extractions, etc., the most significant work was the use of Herculite XRV (restorative composite of uncured methacrylate ester monomers) twice in 1991 and 1992. In 1994, all her remaining original teeth were extracted and replaced with Seal and Bond denture.

**CONCLUSIONS:** JM continued to experience NCS symptoms through 2005 even after the removal of all her original teeth more than 10 years earlier in 1994. Her serum biocompatibility test results indicated that she was highly reactive to Herculite;

a known toxin in sensitive NCS patients (Amin, 2005). We do not know what other dental materials used that she may have been highly reactive to because of unreadable records. The high intensity of JM's symptoms after the removal of her original teeth indicated the involvement of her organ systems in the generation of NCS symptoms. Amin (2006 b) described the role of such "storage organs" in the production of symptoms after the elimination of toxins from the original teeth that are no longer there. In JM's case, this duration lasted for 11 years, between 1994 and 2005. The role of the storage organ is apparently ongoing also while the compromised original teeth are in situ. This is why we, at PCI, insist that patients undergoing dental rehabilitation also to organs system detoxification.

**RECOVERY:** While JM did not do dental rehabilitation (she had none), she was meticulous in implementing our organ system detoxification protocol at least from September, 2005 to October, 2006. On 11-28-05 JM stated that lesions on her leg have "almost completely dissipated." On 1-10-06 she reported that she is "getting better." On 4/24/06, she indicated that "all sores have healed." By July, 2007, all her symptoms have resolved. We consider this case to be a good demonstration of the cause and effect relationship and of the importance of storage organs in the clinical picture of NCS.



**12. DM** (Fig. 13. Sores on the arms of DM extended more intensely to the shoulders. Sites of old resolved sores are marked by loss of melanin. Fig. 14. Appearance of sores and lesions on the legs of DM). White male born in Philadelphia in 1954.

**SYMPTOMS:** We saw DM in December, 2006. At that time, he described his symptoms as follows. "Commencing in February, 2005, I began developing lesions on my legs ... and torso and arms that were pruritic and painful. I also developed bilateral 4X ... edema of my lower extremities that came and went. At first I thought that it was fungus but no treatment helped. My girlfriend does not seem to be affected." Further examination revealed that DM experienced mostly severe intensities of practically all the dermatological and neurological symptoms reported by above patients mostly since February, 2005. However, heart palpitation, vision problems, red-hot face, scalp sores flu-like and arthritic symptoms, inflamed gum tissue, respiratory problems fatigue, nausea, and night fever and sweats started occurring towards the end of 2006. His loss of memory, on the other hand occurred earlier in 1995. DM is strongly allergic to Sulfa. DM. was diagnosed with cutaneous larvae migrans in June, 2006, delusional parasitosis five times during 2006, crab-lice in 1973, and was recently treated for hookworms. He suffered with addictions to medicinal drugs but recovered in 1994.

**DENTAL HISTORY.** DM dental work started since age 5. Available dental records, however, cover the years 2000-2005. During this period, 12 teeth were treated using Dycal; Spersseal; AE, AB2 Bond; TPH; Urethane modified dimethacrylate; and polymerizable dimethacrylate resin.



While most of these materials are known toxins to sensitive NCS patients (Amin, 2005), the Dycal alone is sufficient to have caused NCS symptoms especially in patients allergic to Sulfa like DM (Amin, 2004 b) because of its sulfonamide content. It is regrettable that DM did not do his serum biocompatibility test.

**CONCLUSIONS:** All available evidence points to the dental toxicity being the ultimate cause of DM's symptoms. DM, a highly educated person, however, represents a small number of patients that are unable to change their paradigm from parasitic to toxic causation of their illness. We would have liked for DM to have pursued our protocol for a while to see how it would have worked for him.

**13. LM** (Photos unavailable). White female born in Phoenix, AZ in 1953.

**SYMPTOMS:** When we first saw LM in May, 2007, she was complaining from "itching lesions, very tired, memory, teeth, fibers expel from skin, black specks, eye sight, blood change, confusion." Subsequent examination showed that she had mild to moderate dermatological symptoms of open, oozing, and itchy sores and lesions since 2001 to 2007 with bumps, tracks, peeling skin, scalp sores, fibers, spring-tails, and fungus. Fibers are either fabric fibers or mycelia of fungi like *Madurella* spp. producing "black specks" (mycelial masses and sporangia) (Amin, 2004 a,b, 2006 b). She had moderate pin-prick, movement, and crawling skin sensations and mild brain fog, loss of memory, poor concentration, vision problems, and red hot face since 2001. She also experienced flu-like symptoms, intestinal abnormalities, and kidney problems since 2002-2004, breathing disturbances since 2007, joint and muscular pain and arthritic symptoms since 2003, inflamed gum tissue with painful roots started in 2006. She is sensitive to light and noise, and is frequently fatigued (since 2001) and nauseated (since 2007) with insomnia, psychological trauma, and night fever and sweats since 2004.

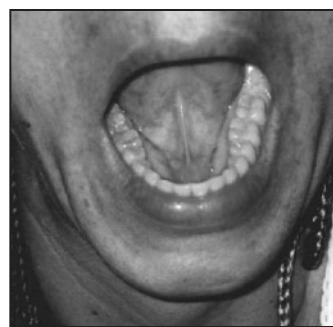
A conversation with LM's sister in May, 2007 indicated that LM has used Crystal Meth in the past but LM stated that she got off of it in 2006.

**DENTAL HISTORY:** LM's dental records were not available but her dentist indicated that he had used Dycal and Life in her dental work in the 1980's. These two liners are notorious causative agents of NCS in NCS patients, particularly those with allergies to sulfa (AMIN, 2003, 2005, 2006 a). We do not know the degree of LM's reactivity to Dycal or Life as the serum biocompatibility test was apparently not done. We also can not evaluate the relative degree of the contribution of Crystal Meth to the expression of NCS symptoms in LM. Such recreational drugs are known to mimic, at least, the neurological symptoms of NCS (Amin, 2006 b).

**CONCLUSIONS:** Despite the lack of adequate records, LM clearly demonstrate a genuine case of NCS involving the use of Dycal and Life and compounded by the unknown contribution of Crystal Meth in the final expression of her symptoms. In a phone conversation with LM in July, 2007, LM indicated that she has not started her dental rehabilitation but is taking our recommended supplements. Our records, however, do not agree with the latter statement.

**NOTES:** We have not been able to follow up on LM's progress except for the few observations noted above.

**14. CR-C** (Fig. 16. The mouth and oral cavity of CR-C; note the color of the gum tissue. Sores were noted on the face, behind the ears, and on the thighs). A white female born in Pasadena, California in 1964.



**SYMPTOMS:** On her first visit to PCI in June, 2004, CR-C complained from "sores, prickling, dizziness, blurred vision (and) scratches that don't heal." Upon close examination, she was found to have moderate to severe open lesions, painful sores elevated tracks, bumps, and fibers since September, 2003. Her neurological symptoms constantly occurred at severe levels of intensity but the date of their first detection was not noted. They included skin irritation, pin-prick, crawling, burning, and movement sensations, compromised memory, concentration, and vision, and brain fog. She also had intestinal abnormalities, joint and muscle pain, arthritic symptoms, and inflamed gum tissue. Her general symptoms included moderate to severe levels of fatigue, nausea, insomnia, night fevers and sweats, psychological trauma, and compromised immune system. A histo-pathological section in February, 2004 from her left ear which was previously diagnosed as cauliflower ear revealed a mild chronic inflammatory infiltrate in a predominantly perivascular pattern associated with cartilage and fibrous tissue. Some of this appeared to be a proliferative fibroblastic reaction. A culture swab of her skin in June, 2004 showed infections with *Staphylococcus aureus* and *S. haemolyticus*.

**DENTAL HISTORY:** CR-C's dental work began in 1978, when she was 14 years old. Dental records were available only since 1994. In 1995 and 1996, three teeth were restored using All Bond A + B, Bisfil 2B and TPH, and Z100, all are dimethacrylate/methacrylate-based, and Delton Hx. Her serum biocompatibility test showed high reactivity to Bisfil 2B and Z100, and Delton Hx. In the post-biocompatibility test restoration, 3M single bend and Esthet-x (to which she was least reactive) were used.

**CONCLUSIONS:** CR-C's dental history, clinical symptoms, biocompatibility test results, and restorative procedure were in complete agreement with causation of NCS as attributed to dental toxicity (Amin, 2004b, 2005, 2006b). It is regrettable that patients have to go through this pain and suffering because of the lack of awareness of some dental professionals of the importance of bio-compatibility testing before dental materials are randomly placed in the mouth of unsuspecting patients. When following our protocol, patients are clearly made aware that symptoms will get worse before they get better. CR-C was a good writer and the following section will reveal her ordeal until recovery set in, in her own words.

**RECOVERY:** "I had my toxic dental work removed in the middle of June, 2004. In the first month following the procedure (PCI protocol), the topical (treatment) helped close and heal most of the open lesions ... there is still something bulging underneath. The (treatment) helped with the new eruptions as well."

"In the second month, I began to experience severe fatigue. My teeth ache. I have gained almost seven pounds ... have less muscle strength. I can see pockets of swelling in my ankles ... my knees. I have become very discouraged and am so tired. Some of my sores begin to heal. When the sores get broken open, they bleed an unusual amount."

“In the third month, my energy is still low. I am feeling very foggy several times a day and experience this vision problem. It is the same as before the dental work was performed. (When I get) a large dose of sun ... my skin improved dramatically. My right shoulder ... became very painful. Yoga ... seems to have broken the concentration of toxins up in my shoulder and it is feeling much better. (At PCI, we recommend lymph drainage massage therapy) ... the breakouts I have are on my ankles, around the knee area, abdomen, face, head.. wrist and hands. My fingernails grow like they haven't for years ... hard and ... fast. I have begun to itch, which was never a symptom of mine before. The teeth that were worked on are very sensitive ... the gums (nearby) swelled up ... and bled and bled. I am sleeping better and have not had night sweats for almost ten days.”

On 9/16/04, CR-C wrote. “My sores have seemed to clean up ... no longer remaining open. I have new ones raise up daily though, ... they don't always break out of the skin. I am (still), having sore lumps on my scalp ... blurred vision, sensitivity to light, and ... severe joint pain. My capability to concentrate, remember, or even focus is so compromised that at times I think I am having dementia.”

On 10/2/04 she stated that the staph infection recurred, some sores resolved, less overall sores, pin-prick and crawling sensations decreased especially in the face. Nails with pin-prick are ridgy, nails without pin-prick are smooth, and that the fatigue was worse right after the dental work.”

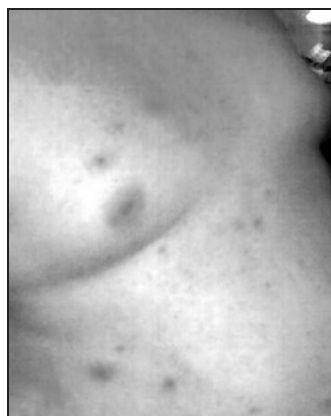On 12/1/05 she wrote “I am doing fine, but have found that it takes years to undo the havoc that toxins have created. I want you to know that I believe that God sent me to you, gave you a gift that you didn't disregard, and because you were willing, have been a turning point in my life.”

On 12/4/05 she wrote “I am feeling good. I am just now at the point where I no longer feel the sensations in my face and chest. It is awesome.”

On 1/15/07 she wrote “I am feeling very good, no sores no sickness and finally no toothaches. It took a long time before I felt good enough to exercise ... I eat the right foods ... get through an hour jog ... it has taken longer than I anticipated to feel “normal” again, but it has come. My life has been turned around since the time of dental work. My sores began healing immediately and my mouth has not peeled once since that day. My energy has returned ... I did feel worse (at the beginning), but then things turned around.”

On 7/28/07 she wrote “I am feeling better than I ever have.”

On 8/3/07 she wrote “I am devoted to your work because I believe that had you not recognized what was going on in my system, I would have died or been ... sent away to a mental hospital.”



15. BS (Fig. 17. Chest and abdomen of BS studded with sores that also covered the body elsewhere). White male born in Alaska in 1970.

**SYMPTOMS:** On August 5, 2005, BS presented at PCI complaining from “rash, itching, sores/dermatitis, nerves twitching, racing heart, redness, hot head, and low grade fever.” Subsequent examination of his clinical picture revealed mild to moderate grade of dermatological

symptoms including lesions, sores, pimples, bumps, tracks, elevated veins beginning in 2002. His neurological symptoms were of moderate to severe grade, first detected later between 2003 and 2005, and included pin-prick, crawling, burning, and movement sensations, compromised memory and vision, body tremors, red hot face, and brain fog. He also experienced heart palpitation, high blood pressure, flu-like symptoms, intestinal abnormalities, breathing disturbances, joint and muscular pain, liver dysfunction, and arthritic symptoms. His oral cavity was also compromised with inflamed gray gum tissue, mucoid secretions, decay, abscesses (above teeth treated with Sealapex), gray teeth and thrush around lips. He noted allergies from penicillin, mold, milk, and electro-magnetic fields. He was also severely fatigued and nauseated, with compromised immune system, psychological trauma, night fevers/sweats, and weight lost since 2002-2003. He was previously diagnosed with depression and asthma in 2004. A skin culture in August, 2005 from his abdomen was positive for *Candida* sp. and *Staphylococcus aureus*. Another culture from the scalp was positive of *S. aureus*, *S. alfabemolitica*, and *candida* sp.

**DENTAL HISTORY:** Fifteen of BS's teeth were treated with a large number of dental materials between 1995 and 2005. Eleven dental compounds were used as follows: Gutta Percha (on 5 separate occasions starting in 1996), Temp Bond (10, 1995), Fuji 1 (10, 1996), Clear Fil (2, 1993), Durelon (1, 1995), Sealapex (4, 1996), Tetric Flowable composite (1, ?), Filtek (1, ?), Herculite (2, 2001), and Probond (2, 2000). His blood bio-compatibility test demonstrated hyper-reactivity to , Durelon, Gutta Percha, Clear fil, Sealapex, Tetric Flowable composite, Filtek, and Herculite. While his bio-compatibility test indicated that he is ok with Epifany, the MSDS sheets state that Epifany should not be used in people allergic to methacrylates. BS is allergic to Herculite and other compounds made of methacrylates. See Amin (2005) for the chemical composition of these dental materials. BS also proved to be highly reactive to other dental materials, especially Balsam Peru, which is used in various dental cements, as has been demonstrated via delayed patch testing over 5 days.

**CONCLUSIONS:** BS presents an excellent case of documentation of NCS clinical symptoms associated with dated dental causes making it possible to estimate the incubation period at about 8 years. It is amazing and shocking to observe his quality of life so degraded with so many dental chemicals without having considered running a bio-compatibility test. That test was only made after the damage was done and after consultation with us at PCI; it is a crime. No wonder that BS has become an activist and is making dental advocacy his life quest. He is making waves, at the state (Utah) and national level. He has also created a new web site addressing such dental issues; see <http://informed.securesties.com>.

**RECOVERY:** BS's own words provide a telling account of his progress. On 10/21/2005 BS wrote “I was able to get an appointment with Dr. ... (Dentist).. I did get tested for dental material compatibility ... I am taking the Ubichinon ... 3 times a day which helps tremendously ... I actually replaced the antidepressant Symbiax which I was taking with it because it works a ton better and does not give me the side effects of the antidepressant.. Still have staph and *candida* sp. infection (identified) from the skin test. A skin rash at times. Also a white tongue at times and smelly teeth.”

On 3/13/2006 BS wrote “still having nervousness at times and problems sleeping. Up every (2 to 4) hours. I do have a rash on my left leg.”



On 5/25/06 BS wrote “some of the products in the same chemical family to avoid were Eugenol. The dentist who did the crown building on my teeth saw Eugenol when to do tooth # 20. He removed it and it made a tremendous difference to improvement in my health. I have been waiting for a relapse but it has not come ... Back pain is gone. Nervousness reduced dramatically. Sleep Apnea going away. Constipation disappearing. Able to dream for the first time in years. Reduced allergy reactions. White tongue almost gone. I unfortunately did not see Eugenol as being incompatible on my ... dental testing report and will need to call them to ask why? I do recall it coming up as something my body does not like on a MSA test (Meridian Stress Test machine) by a local naturopath 2 years ago ... the naturopath.. thought my problem was mercury ... and I went out and had most of silver fillings redone without knowing what to replace them with and how to replace them (that got me into more trouble). I probably had Eugenol and other incompatible stuff put in the teeth as replacement.”

On a subsequent phone conversation, BS stated that his “scalp sores are all but gone.”

On 8/14/2007 BS wrote “ I have been rather conservative in following rehab program. Removing materials and teeth as I experienced problems. I took out the sheet that you had compiled for me with the teeth and the problematic materials. It was interesting to see that they match exactly. I have removed some of the problematic teeth and improve when I do so. The current problems ... outlined by my dentist match the same teeth you had specified. It was neat to see this and show others. I wonder if these allergic/ toxic materials are responsible for the holes in my jawbone that the oral surgeon found recently? Nico/cavitations?”

BS is clearly in the final stages of his complete recovery. He would have already made it completely by now if it was not for his piece meal conservative approach in treatment.

**16. KS** (Photos unavailable). White female from Arizona born in California 1965.

**SYMPTOMS:** In October 23, 2002, KS complained from “moving, scales, hair moves ... under skin.” Upon further examination, KS appeared to have been experiencing typical dermatological and neurological symptoms compatible with those found in NCS cases especially sores, facial lesions, crawling and pin-prick sensations first noted in March, 2002. She was previously diagnosed with scabies and hook worms and treated with Acticin and Mebendazole, respectively based on symptoms alone but no parasites were actually recovered or identified. She was also diagnosed with mental disorder and psychosis and put under psychiatric care in a mental facility for weeks until helped out by OMA.

**DENTAL HISTORY:** Cemented veneer in tooth # 24. The tooth was extracted in early November, 2002.

**CONCLUSIONS:** This is one of the very few cases we encountered where NCS symptoms were associated with only one tooth that could be documented. Sometimes, this is all it takes to develop clinical NCS symptoms. It largely depends on the toxic dose of an incompatible dental element used (Amin, 2004 a,b). It is unforgivable that KS is made to suffer in a mental institution for weeks because of misdiagnosis by medical political, and social institutions that are supposed to help rather than criminalize genuine clinical cases like KS. While institutionalized, she lost custody of her two children as well as her home; she was not allowed to attend court proceedings.

**RECOVERY:** KS experienced one of the fastest recovery rate that we have observed once tooth # 24 was extracted in early November, 2002. She reported 50% improvement one day post-extraction and 85% improvement by January 2003 and 100% recovery shortly thereafter. We regret to have lost contact with KS since; her new contact information were not available.

**17. MSh** (Fig. 18. A facial sore on the face of MSh). White female born in 1961, from Corpus Christi, Texas.

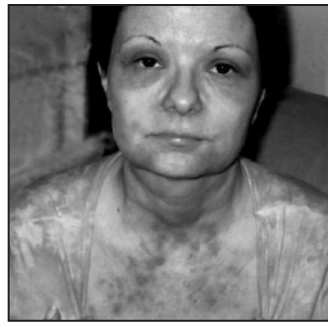**SYMPTOMS:** In December, 2006 at PCI, MSh was complaining from “facial and scalp lesions carrying Staph or Strep infections X14 yrs or greater. Lesions would get better then they would worsen. Scalp lesions would itch or tickle even after shampooing. Lesions would erupt from deep within my skin. Slow healing wounds since August 2006 on face and scalp. On antibiotics nearly continuously since 1992 or better.” Her skin symptoms were actually first detected between the late 1980’s to 1992. Springtails, fibers and fungus were first Observed in November, 2006. She also experienced crawling and movement sensations, brain fog, poor concentration and compromised vision and memory. She had high blood pressure, flu-like symptoms, intestinal abnormalities, joint pain, inflamed gum tissue since October/November, 2006. She was sensitive to metals and mold since the mid-1990’s. She was also fatigued and with psychological trauma.

MSh was previously diagnosed with depression in the mid 1980’s, cervical cancer in 1986, and had radical hysterectomy (resolved), ADD in mid 1990’s, Gerd in 2000, high blood pressure in 2003 for which she was treated, had nissenfundoplication in 2003 (resolved). She has a history of being heavily medicated with antibiotics including E-mycin, Acromycin, Athersin, Permethrin cream 5%, Permethrin shampoo, and recently self-medicated on heavy metal detox and UV light via tanning bed. She has no history of recreational drug use.

**DENTAL HISTORY:** MSh’s dental history goes back to 1971, but her more recent dental work since 1996 shows the use of Fuji, Temp Bond, Temp Cement, Hydroxethyl methacrylates, and Apex Sealer. See Amin (2005) for toxicity of these; among other dental materials in sensitive NCS patients. We have no evidence that she had made a bio-compatibility test and are thus unable to ascertain her degree of reactivity to dental materials used. She did, however, take the initial package of supplements and detoxification agents recommended in our protocol.

**CONCLUSIONS:** Despite the lack of follow up with our treatment protocol, MS’s case nevertheless, represents another example of the causal relationship between toxic dental materials and the expression of NCS symptoms in susceptible patients even though the specific ingredients in the dental materials used cannot be ascertained because of lack of biocompatibility data. At the time of this writing, we have no information about the progress in MS’s case.





**18. MSt.** (Fig. 19. MSt shortly before the onset of symptoms in 2006. Fig. 20. Sores covering the face and chest of MSt during the height of her symptoms in July, 2006. Note the edema and the red hot reaction). White female born in Philadelphia in 1955.

**SYMPTOMS:** When examined at PCI in July, 2006, MSt was diagnosed with “classical symptoms of NCS, especially dermatological ...” Dermatological symptoms were of constant nature and started in April, 2006. They were of moderate to severe intensities and included open oozing, and painful sores and lesions on the face, ears, neck, chest and arms, and elevated ripples and veins especially on the hands. In May and June, 2006 her neurological symptoms started manifesting also at moderate to severe levels of intensities. These included skin irritation, pin-prick, crawling, burning, and compromised memory and vision, and brain fog. The only organ system compromised was the digestive system. She also experienced severe swelling and noted moderate to severe sensitivity to Sulfa, bright light, mold and humidity. She was fatigued and suffered from insomnia, compromised immune system and some weight loss. A swab culture from her chest was positive for *Staphylococcus aureus* and *S. epidermidis* on July 26, 2006. On May 31, 2006, her physical exam and laboratory blood work were normal but she was diagnosed with “multiple food allergies with a development (of) an erythematous rash, with wheat and gluten sensitivities suggestive of Celiac disease.” “She has been tested for Celiac antibodies, which have been negative although she reports that she was on prednisone therapy and gluten-free diet and she is unsure about and is questioning the results from the serological testing ... There is no family history of Celiac disease.”

MSt provided a chronological narrative of her symptoms and clinical history in 2006 which is very telling. Relevant parts of MSt’s account are summarized. 3/22. Dentist removed & replaced three large amalgam fillings and placed “surface composite on the two front teeth.4/4-5. “Noticed a small red, raised itchy patch behind my left ear. Also my upper chest was itchy, but no rash. Applied OTC anti-itch cream behind ear. Rash continued but would almost go away (temporarily) when I applied OTC steroid cream.” 5/2. “Presented to primary physician with red, raised, itch rash. Script given for Hydroxyzine 25mg and Mometasone Furoate.” 5/11. “Presented to allergist for rash on ears, eyes, nose and chest.” 5/15: “Rash became so intense and spread across my face, neck, ears, upper chest and inside right forearm. Throat began to itch. Presented to ER. Received a shot of Solumedrol, shot of 50 mg Benadryl and given a script for Pepcid, Prednisone, and an Epi pen.” 5/19. “Script was given for Celiac spruce antibiotics blood test.” 5/25. “Rash was worse than when I went to ER, extreme pain and itching. Described feelings of a *pin-pricking* my skin were the rash was and unable to sleep even with Benadryl round the clock. Script given for Avelox and Presudovent.” 5/30. “allergist office ... antigen drops X 3 vials.” 6/5. “allergist office ... presented with severe rash. Evaluation: urticaria. Recommend IV therapy starting today. Begin IV 25 grams vitamin C plus (2 times per week). 6/5. “GI consult. Repeat Celiac antibody

test.” 6/13. “IV 25 grams plus.” 6/15. “IV 50 grams plus. Told the allergist that I may be having a reaction to something in the IV or the dosage. Described the intense facial swelling within 2 hrs. Of the completed IV. Was told he never heard of the reaction. Recommended continuing with therapy.” 6/20. “Told them I was d/c the IV therapy for now. Script for Ultra Flora, graphite drops and antigen drops. Stated my problem was “allergic dermatitis.” 7/6. “at primary physician office: eyelids swollen and slit at the crease. In severe pain whenever the rash was present. I told him I can’t sleep more than a couple of hours because of the pain and pin-pricking feeling. I am exhausted, eating only one meal a day, constantly groggy from the antihistamines round the clock..the internet ... wondered if there was a connection with having a new dental material placed in 3 teeth ... I came across a link to PCI. The case histories and photo’s described my symptoms and looked like me. Symptoms started shortly after having the material placed in my mouth.”

Summary of narrative since MSt’s visit to PCI on July, 2006. 7/12. Physician presented with NCS information but stated that he “never heard of NCS and believes I have been scammed.” Will not write for massages (since) ... I have not been diagnosed with lymphatic or breast cancer.” 7/12. “Informed (allergist) that I would no longer seek treatment as I have been diagnosed with NCS. Described what NCS is to the office staff. I also told them that the IV vitamin C (5 grams) therapy I have been receiving twice a week was making my symptoms worse.” 7/19. “Prescribed a 20-day course of Prednisone, clobetasol ointment 0.05% (bid).” 8/11. “Patch test ... all negative. I reminded them that I have been on Prednisone, which would suppress reactions. Dr’s still will not read the PCI materials I gave them on 7/19. Stated they are not interested in an “unknown” and “unproven” diagnosis. 8/12. “First lymphatic drainage massage performed (after therapist contacted Dr. Amin for specific instructions).” Massage performed weekly for the next few months. 8/17. “(punch biopsy of skin on lower left jaw) pathology report “spongiatic dermatitis” of unknown etiology. Physician debunked the idea of NCS again. Was told that I may never know what the causative agent for the skin rash and lesions ... I told them that I would not take a steroid, which may (only) suppress my symptoms, not address the reason I was having the severe dermatological problem, i.e., NCS, and a wreak further damage to my organs and immune system in the long run.” 8/19. (Dentist) removed dental materials placed in my mouth on 3/22.” 10/7 “(Dentist) matched bonding on front teeth, as these were also part of the 3/22 dental work performed.” 10/23. “Compound pharmacist: Thyroid and bio-adrenal function has been impaired. (NCS) supplement schedule provided. Advised to remain on NCS protocol.” 10/24. (Dentist) replaced bonding material on front teeth from 3/22.” 11/30. “Consult.. with new primary physician. (He) encourages complimentary/alternative therapies. (He) has not heard of NCS but would like time to read the printed materials I have provided. Recommended I continue with NCS protocol if that has helped.”

MSt’s narrative came to an end as she got busy following up on her protocol. Her reporting picks up in August, 2007; See section on recovery following.

**DENTAL HISTORY:** MSt’s dental history extended only to 3/22/06 when four teeth (nos. 8, 15, 18, 19) were treated with Esthet-X improved Micro Matrix Restorative (including Titanium Dioxide and Urethane modified Bis-GMA dimethacrylate) (tooth no. 8); One step ( including Biphenyl dimethacrylate and Hydroxyethyl methacrylate), Clearfil composite (including Bisphenol A diglycidylmethacrylate and Triethylenglycole dimethacrylate), and Biscover liquid polish (no methacrylate-



based compounds) (teeth no 15, 18, 19). While the bio-compatibility test results indicate that MS was only highly reactive to Esthet-X we believe that her reactivity may have been to the methacrylate-based compounds in all dental materials used except the Biscover polish but definitely to the Titanium dioxide found only in Esthet-X to which she was highly reactive. MSt had no other dental work done prior to 3/22/2006.

**CONCLUSIONS:** The case MSt represents one more case in which the relationship between the dental materials used (cause) and the manifestation of NCS symptoms (effect) are well documented. The dental work on 3/22/2006 was closely followed by the first appearance of symptoms only six weeks later on May 2, 2006. This time frame marks one of the shortest incubation periods that we have observed. This short incubation and the severity of symptoms reflect the high intensity of MSt's allergy to the toxic dental materials used. Duration of incubation period in NCS patients varied between a few hours to 28 years (Amin, 2006 b.). The case MS also represents the trials and tribulations, pain and suffering that unfortunate individuals seeking medical help have to go through to regain their health back. It is criminal to expose suffering patients to all the wrong procedures and medicines because of the arrogance and misinformation of some medical professionals.

**RECOVERY:** MSt wrote (to Dr. Amin) "It occurred to me that you may want a current photo devoid of rashes, sores, broken or inflamed. Sort of a "before" and "after" for your files ... The area just behind both ears is still very sensitive in that it will become very red, somewhat raised and itchy at times. I have recently found out that I can not wear earrings that have surgical steel or titanium, even though they may be gold plated. My ear lobes become very red and hot and itch so intensely that I cannot get them out fast enough. This was never the case before 3/22/2006." This intense reactivity to Titanium earrings supports the above suggestion that is was Titanium dioxide in the Esthet-X that may have set off the NCS symptoms in the first place. In a telephone conversation with the PCI office in July, 2007, MS said that she was feeling "fantastic." On 8/11/2007, she wrote "Your diagnosis and NCS protocol has helped me to regain a state of wellness in a relatively short time. I continue to improve and believe that diligence to this protocol will ensure that I never experience such an impaired, depilating lack of good health in the future. My husband says I am a walking "poster child" for the benefits strict adherence to the protocol you have developed. Sincerely and gratefully."

### General Conclusions

The discussed cases, as different as they are, have one thing in common: the verification of the cause and effect relationship establishing dental toxins as the primary cause of NCS symptoms. Of the cases presented, 6 cases (nos. 5, 11, 14, 15, 16, 18) methodically followed our protocol and completely or nearly completely recovered; a 100% recovery rate. In 3 other cases (nos. 2, 4, 10), patients have partially recovered as their protocol was not completed. In cases where complete documentation was available, it was observed that dermatological symptoms usually preceded neurological symptoms. Only in chronic cases of longstanding, organ systems also suffered symptomatically. Detailed dental histories, the ordeal of symptomology and the long trip to recovery are best expressed in cases no. 14, 15, and 18. I have great sympathy for what those brave patients go through to reclaim their health, and great disdain for the so called health professionals who give medicine a bad name. I have not been bashful about expressing my professional opinion or my feelings. 🌸

### Acknowledgments

I am grateful to all my patients who trusted me for the caring of their health and wellbeing and allowed me to use their informations and photos for the benefits of others. John Dale, PCI, typed the first draft of this manuscript.

### REFERENCES

- Amin, O.M. 1996.** Facial cutaneous dermatitis associated with arthropod presence *Explore* 7: 62-64.
- Amin, O.M. 2001.** Neuro-cutaneous Syndrome (NCS): a new disorder. *Explore* 10: 55- 56
- Amin, O.M. 2003.** On the diagnosis and management of Neuro-cutaneous Syndrome(NCS), a toxicity disorder from dental sealants. *Explore* 12:21-25.
- Amin, O.M. 2004 a.** Dental sealant toxicity: Neurocutaneous Syndrome (NCS), a dermatological and neurological disorder. *Holistic Dental Association Journal* 2004: 1-15.
- Amin, O.M. 2004 b.** On the diagnosis and management of Neuro-cutaneous Syndrome, a toxicity disorder from dental sealants. *California Dental Association Journal* 32: 657- 663.
- Amin, O.M. 2004 c.** On the course of Neuro-cutaneous Syndrome (NCS) and its pseudo diagnosis by medical professionals. *Explore* 13:4-9.
- Amin. O. M. 2005.** Dental products causing Neuro-cutaneous Syndrome (NCS) Symptoms in NCS patients 14: 57-64.
- Amin O. M. 2006 a.** On the diagnosis and management of Neurocutaneous Syndrome (NCS), a toxicity disorder from dental sealants. *Townsend Letter* 276: 85-90.
- Amin, O.M. 2006 b.** An Overview of Neuro-cutaneous Syndrome (NCS) with a special reference to symptomology. *Explore* 15: 41-49.

### About the Author



Dr. Amin earned his B.Sc. in Botany and Zoology and M. Sc. in Medical Entomology from Cairo University, and Ph.D. in Parasitology from Arizona State University. His professional training started at the US Naval Medical Research Unit #3 (NAMRU-3), Cairo as a Research Assistant in Medical Zoology. His post-doctoral work was at Old Dominion University, Norfolk. He subsequently worked at the University of Wisconsin as a Professor of Parasitology, Allied Health and Biology for 20 years. In 1992, he founded the Institute of Parasitic Diseases (IPD) (for research and clinical testing of human parasites). He has a joint laboratory facility in Mexico and Mali, West Africa as well as continued research association with NAMRU-3 in Cairo.

Dr. Amin is a nationally and internationally recognized authority in Parasitology. He specializes in the systematics, ecology and pathology of protozoans, helminths and arthropods. He has published over 145 major articles/book chapters/teaching videos on parasites from North America, Peru, Chile, North, South and East Africa, Persian Gulf, the Middle East, Taiwan, Japan, Thailand, Vietnam, Inner Mongolia (China), Russia and India. He is an active lecturer on parasitological and related disease topics to health care professional, allied health workers and medical students in seminar and workshop settings.

Dr. Amin is an active member in the American Society of Parasitologists (and its Rocky Mountain affiliate), British Society of Parasitology, Entomological Society of America, Helminthological Society of Washington, American Microscopical Society, Microbiology and Arizona Homeopathic and Integrative Medical Association.